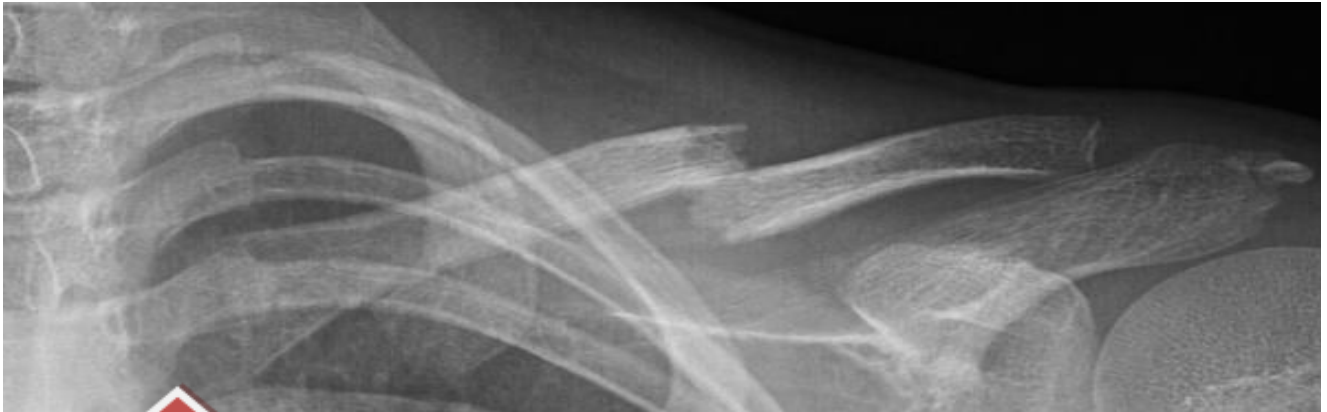
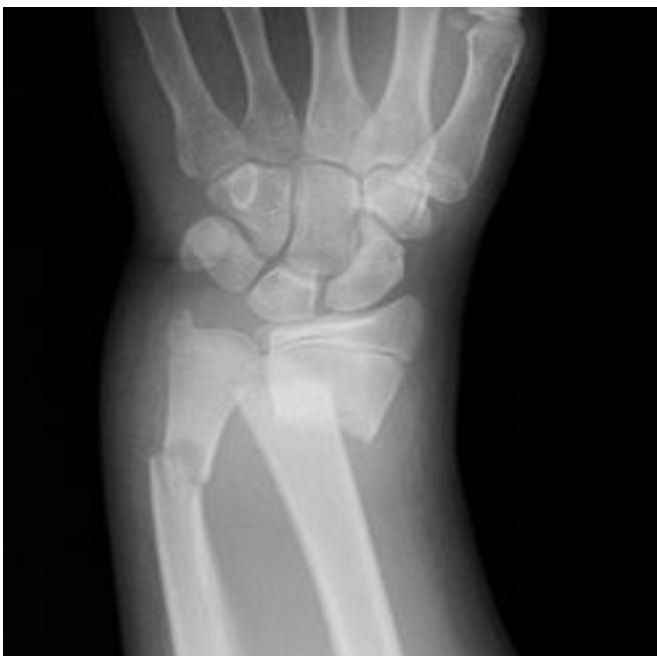
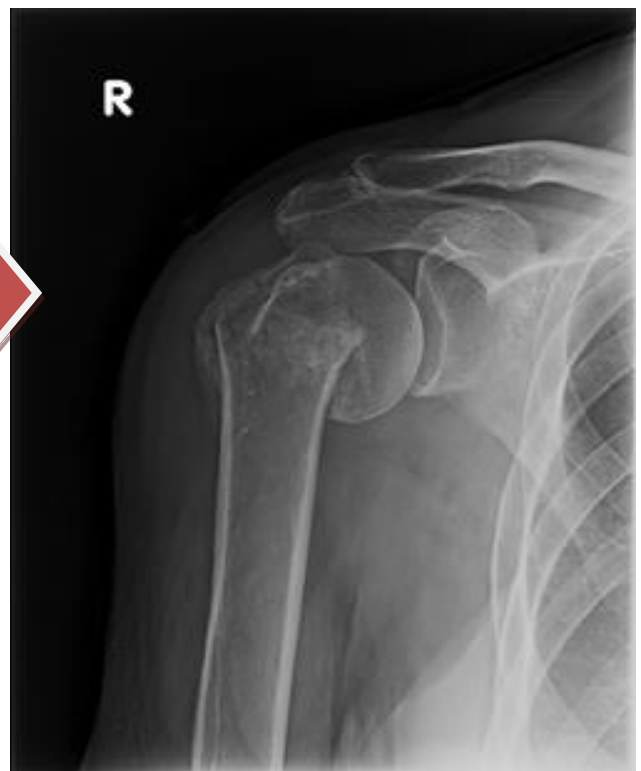

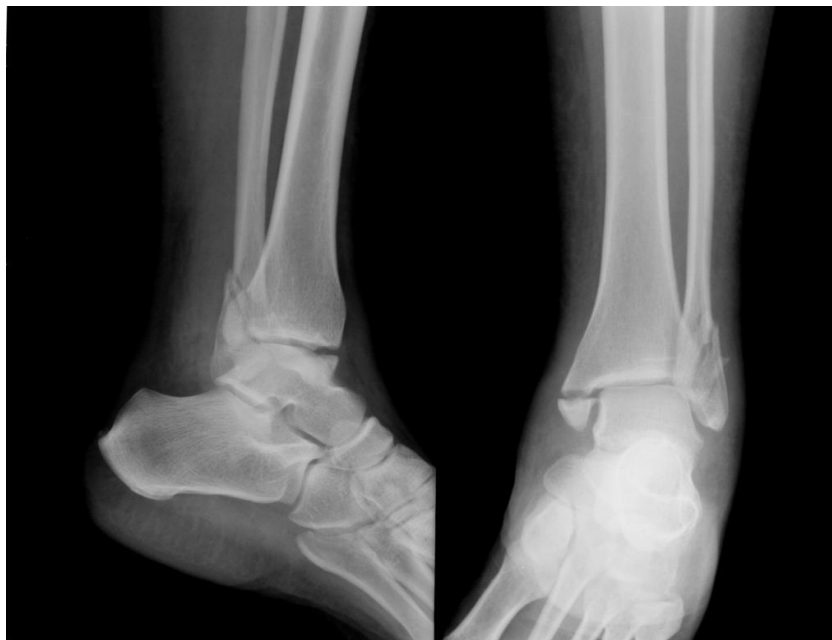**Clavicle Fracture and Neck of Humerus Fracture**

Both of these fractures usually only require a polysling and Virtual Fracture Clinic follow- up



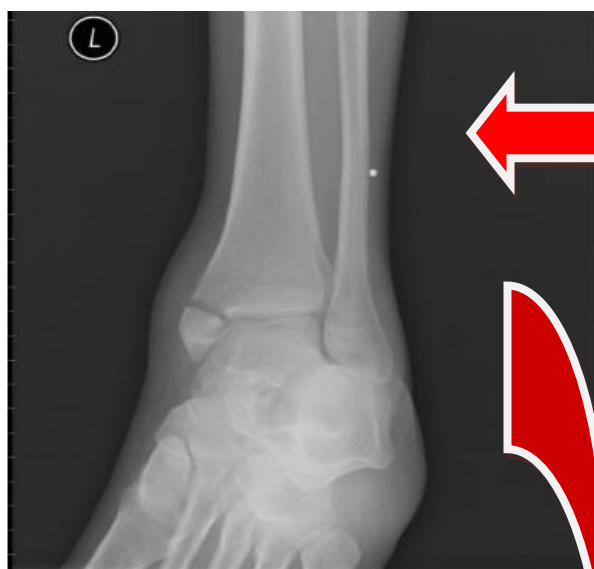
**Displace Radius & Ulna Fracture**

Grossly unstable fracture  
Ensure sensation documented prior to action.  
Backslab and admit to Orthopaedics for ORIF



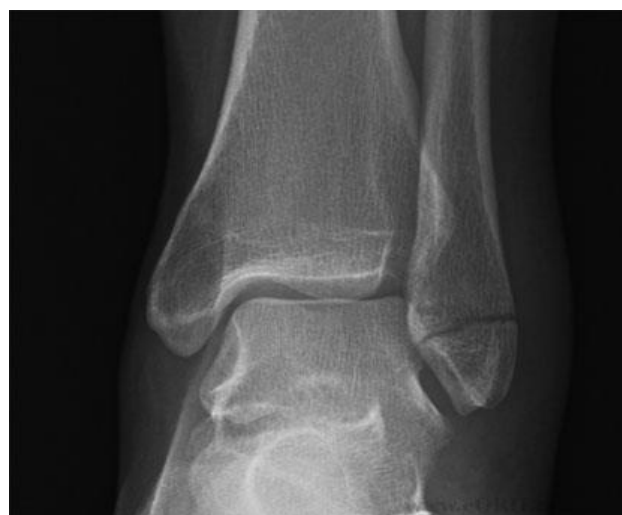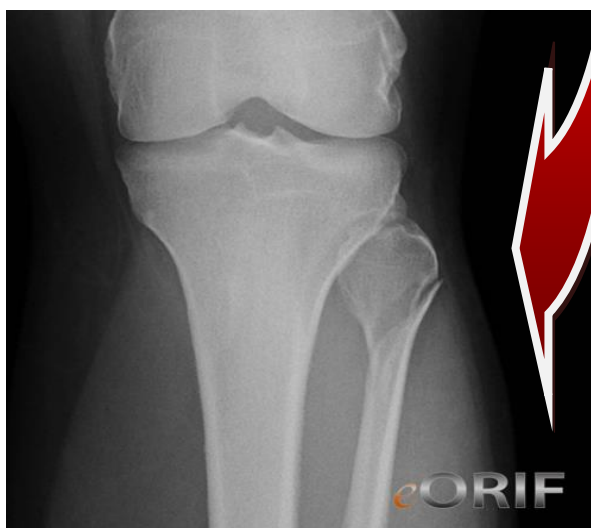### Trimalleolar Fracture

Occasionally these present to minors. These are highly unstable fractures. If there is talar shift- unequal distance between the talus and malleoli, they need manipulation in Resus. Even if there is no talar shift they will usually need to go to Resus for analgesia and a backslab.



### Isolated Medial Malleolus Fracture

Be wary if you see an (apparently) isolated medial malleolus fracture. They are often associated with a proximal fibular fracture.



### Undisplaced Lateral Malleolus Fracture

On the other hand a moonboot and Virtual Fracture Clinic referral will usually suffice for an undisplaced lateral malleolus fracture