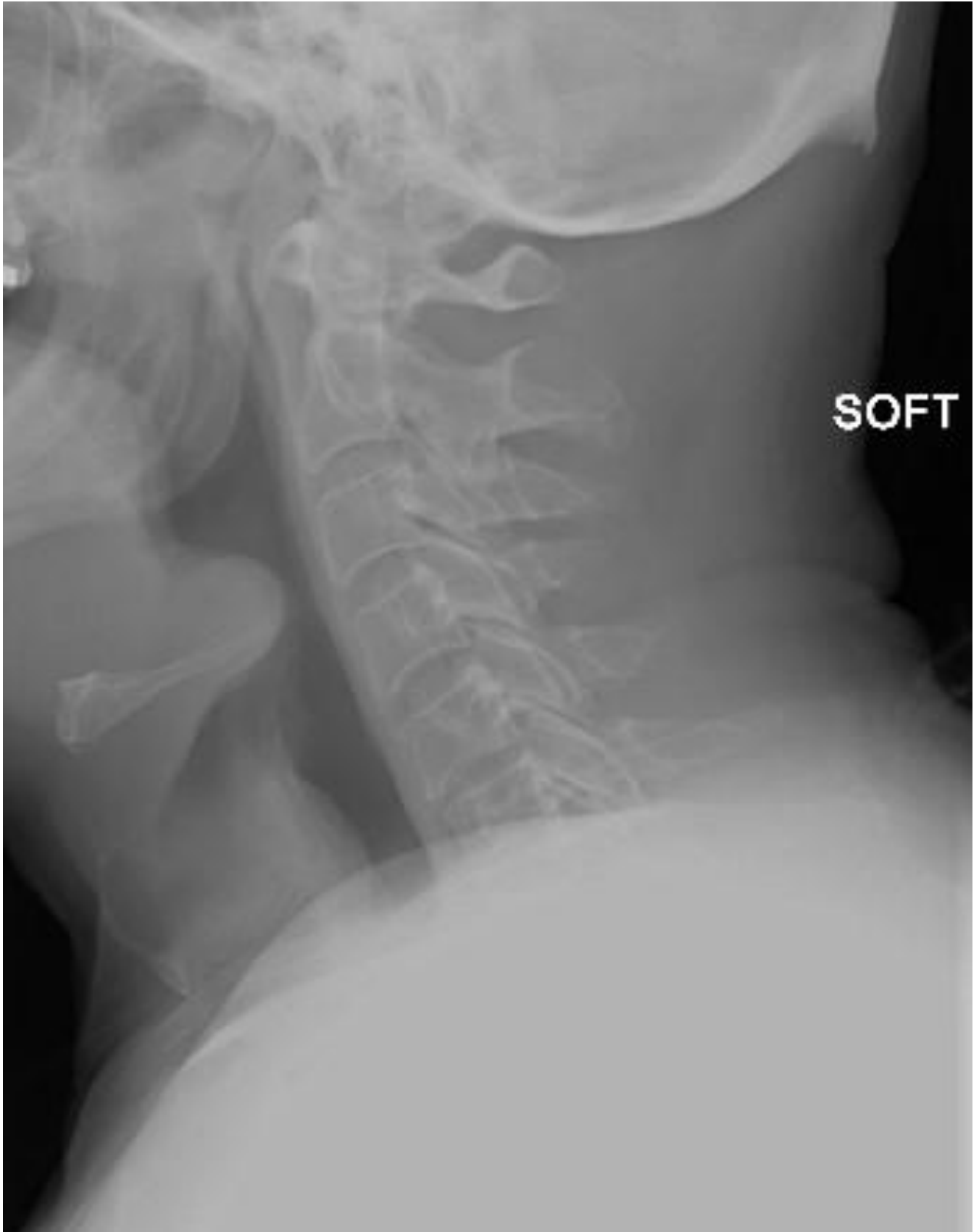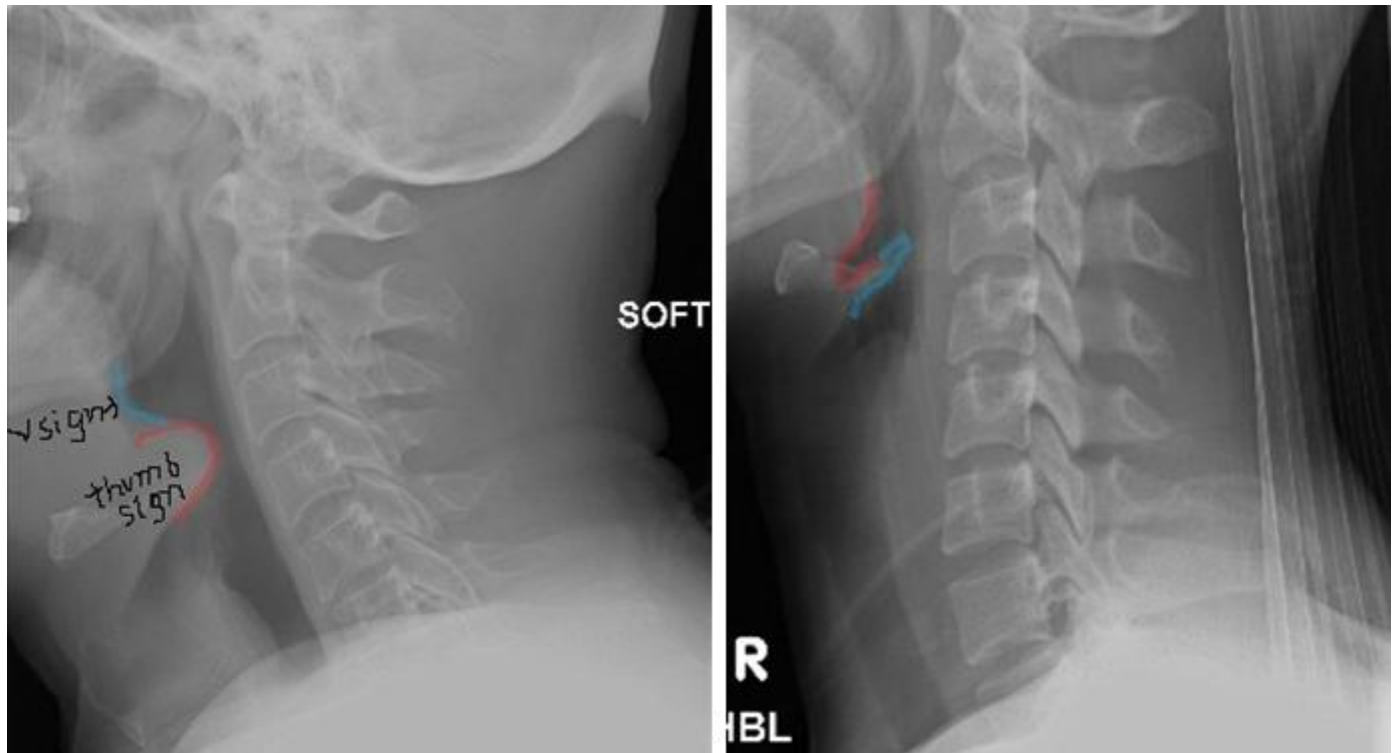


A 63 year old man presents with stridor and dysphagia. What does the XR show?



Answer: Epiglottitis



Left: thumb sign and loss of vallecula. **Right:** normal for comparison.

Disclaimer!

Epiglottitis is an ENT emergency and should be diagnosed clinically if possible.

XR should only be performed if another diagnosis is being sought, for example retropharyngeal abscess or foreign body.

XR Signs in Epiglottitis

- Enlarged epiglottis (thumb sign)
- Loss of vallecular space
- Thickened aryepiglottic folds
- Distended hypopharynx
- Straightening of the cervical spine

Management:

- Do not upset the patient or examine the throat.
- Call anaesthetics and ITU to help obtain a definitive airway.
- Humidified O₂.
- Nebulised adrenaline (0.5ml/kg 1:1000).
- IV antibiotics.